

Post-Operative Complications of Traumatic Thoracolumbar Spine Surgery: Experience of the P11 Neurosurgical Emergency Department—CHU Ibnou Rochd Casablanca (2018–2022)

Khadija Elguettabi¹, Pr Jamal Ouafaa², Ibtissame Faham¹, Amine El Khamouye^{1,2,*}, Nassima Dait¹, Oumaima Bouhou¹, Abdelmajid Chellaoui², Abdessamad Naja², and Abdelhakim Lakhdar²

ABSTRACT

This retrospective study focuses on 110 cases of thoracolumbar trauma operated on between 2018 and 2022 in the neurosurgical emergency department. The objective is to analyze the complication rates of surgery for traumatic thoracolumbar spine pathology, identify high-risk patients and understand these complications in order to improve preoperative planning and advice to patients for better care. The results show that the frequency of complications of thoracolumbar spine surgery in this department was 28.18%. The average age of patients with complications was 41.5 years, with a male predominance (65%). The main complications were post-operative infections (38.70%) and discharge of pus through the surgical wound with infectious syndrome (32.35%). The most frequent pathological histories in patients were toxic habits (alcohol and chronic smoking), diabetes and psychiatric disorders.

Keywords: Complications surgery, thoracolumbar spine surgery.

Submitted: May 15, 2024

Published: July 26, 2024

 10.24018/ejmed.2024.6.4.2132

¹Neurosurgery Department, CHU Ibnou Rochd Casablanca, Morocco.

²Neurosurgery Department, CHU Ibnou Rochd Casablanca; Laboratory for Research into Diseases of the Nervous and Neurosensory Systems and Disability, Faculty of Medicine and Pharmacy, Hassan II University of Casablanca, Morocco.

*Corresponding Author:

e-mail: elkhamouyeamine@gmail.com

1. INTRODUCTION

Spine pathology is a common cause of hospitalization in the neurosurgical emergency department. This study details the complication rates of traumatic thoracolumbar spine pathology surgery at the ward aimed at identifying patients with high risk and understanding these complications to improve preoperative planning and patient advice for better management.

Our work is a retrospective study of 43 complicated cases of dorsolumbar spine trauma operated on among 218 patients in the Neurosurgical Emergency Department of the Ibn Rochd University Hospital in Casablanca, spread over a 5-year period from January 2018 to December 2022. In this study, we evaluated the long-term results of patients with thoracic and lumbar spine fractures treated by posterior osteosynthesis, considering that the long-term consequences of these fractures may be underestimated

while studying the epidemiological, clinical and paraclinical profile of patients in this series who developed a complication of dorsolumbar spine surgery, and finally comparing the results of this study with data in the literature.

2. METHOD

The study consists of a descriptive retrospective study which was carried out on the files of patients from January 1, 2018, to December 31, 2022, hospitalized in the neurosurgical emergency department of the Ibnou Rochd hospital, including patients operated on for thoracolumbar trauma during the above-site period and reconsulting for complications, we exclude patients operated on in other departments or other private and public hospital structures, which enabled us to identify 31 cases of patients having had a complication out of 110 patients operated on

in the same period. This is for an analysis of epidemiological, clinical, and paraclinical data as well as the different complications, their therapeutic management, and their evolution.

3. RESULTS

Between January 2018 and December 2022, 218 patients were admitted to the Neurosurgery departments of CHU Ibn Rochd de Casablanca for dorsolumbar trauma and underwent surgery.

Nevertheless, 43 of these patients had various complications, representing a frequency of complications of post-traumatic dorsolumbar spine surgery of 19.72% of cases in our series.

The mean age of patients who had a complication after traumatic dorsolumbar spine surgery was 41.43 years, with extremes ranging from 16 to 80 years. The age group most affected was between 16 and 30 years, corresponding to 32.56% of the total number of patients in the series.

In our series, most patients who developed a complication after post-traumatic dorsolumbar surgery were under 30 (14 patients), corresponding to a frequency of 32.56%. This age group was followed by the 31–40 age group (10 patients) with a frequency of 23.26%, then the 41–50 age group (6 patients), the 51–60 age group (6 patients) with an identical frequency of 13.95%, and finally the over-60 age group (7 patients) with a frequency of 16.28%. 32 male patients (74.42%) and 11 female patients (25.58%), giving a sex ratio of 2.90. The most frequent antecedent condition was chronic smoking (for more than 10 years) in 13 patients (30.23%), diabetes in four patients (9.30%), three cases of alcoholism (7.00%), four cases of psychiatric disorders (9.30%), hypertension in three patients (7.00%), two cases of Cannabis users (4.65%), two patients with a history of treated pleuropulmonary tuberculosis (4.65%), one case of operated fourier's gangrene (2.32%) and one last case of Psoas Rhabdomyosarcoma treated by surgery and neoadjuvant and adjuvant chemotherapy (2.32%).

In our series, the clinical signs that led to the diagnosis of complications after post-traumatic dorsolumbar spine surgery were dominated by spinal pain (dorsalgia and lumbago), with a frequency of 41.86%. Followed by pus discharge through the surgical wound (37.20%), infectious syndrome (27.90%), lumbosciatica in 16.28% of cases, paraparesis in 23.25% of cases, then paraplegia (20.93%), spinal syndrome (16.28%) and sensory disorders in 18, 60% of cases respectively, genital-sphincter disorders and exposure of the osteosynthesis material in an identical manner in 9.30% of cases, and finally the abutment of the osteosynthesis material in 6.98% of cases.

In the event of a mechanical complication, most patients (18 out of a total of 25 patients, i.e., 72% of cases) experienced chronic back pain and/or lumbago that was resistant to analgesics, as well as a neurological deficit on admission in all patients in our study series, and finally genital-sphincter disorders in 4 cases (16%).

Mechanical complications were dominated by secondary displacement of osteosynthesis in 13 cases (Fig. 1) (52% of cases), followed by unravelling of the osteosynthesis material (Figs. 2–4), notably exposure of the latter in 4

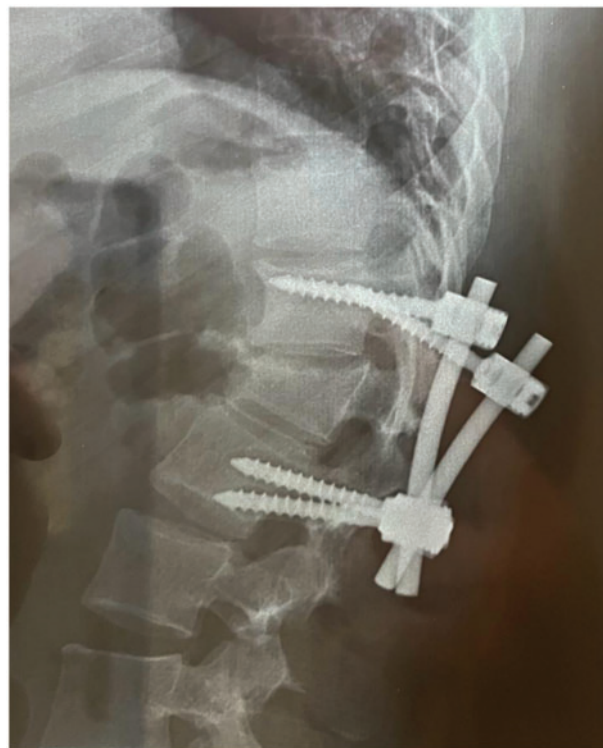

Fig. 1. Standard radiograph of the dorsolumbar spine in profile, showing dislocation of the osteosynthesis material.

cases (16%), and abutment of the osteosynthesis material against the skin in 5 cases (20%). In our series, we also noted 2 cases of vertebral compression with osteosynthesis material in place (8%) and 1 case of degenerative disc disease (4%).

Infectious complications are manifested by fever, chills, altered general condition, pus associated with loosening of sutures or serous and/or serohematous secretions, and sometimes inflammatory signs of inflammation around the surgical wound or swelling.

Many of our patients who presented with an infectious complication had fever on admission ranging from 38 °C to 40 °C, i.e., 12 patients (57.14%).

On examination of the surgical wound, 15 patients (71.42%) showed pus discharge. In addition, 04 cases had exposed osteosynthesis material (19.04%).

Three patients, or 14.28% of cases, had a neurological deficit associated with a spinal syndrome. In these patients, walking was impossible; they could not hold the Mingazzini, and the FMS was estimated at 02/05.

Bacteriological tests to identify the causative organism were carried out in all patients in our series with a post-operative infectious syndrome involving pus or exposed pus or exposed osteosynthesis material on clinical examination. This analysis was positive in ten patients in our series, i.e., 47.62% of cases with an infectious complication. Nevertheless, germ testing was conclusive in 12 cases. In six cases, it was staphylococcus coagulase-negative, three cases of staphylococcus aureus, two cases of multi-resistant *Pseudomonas aeruginosa* and a single case of *Escherichia coli* sensitive only to Amikacin.

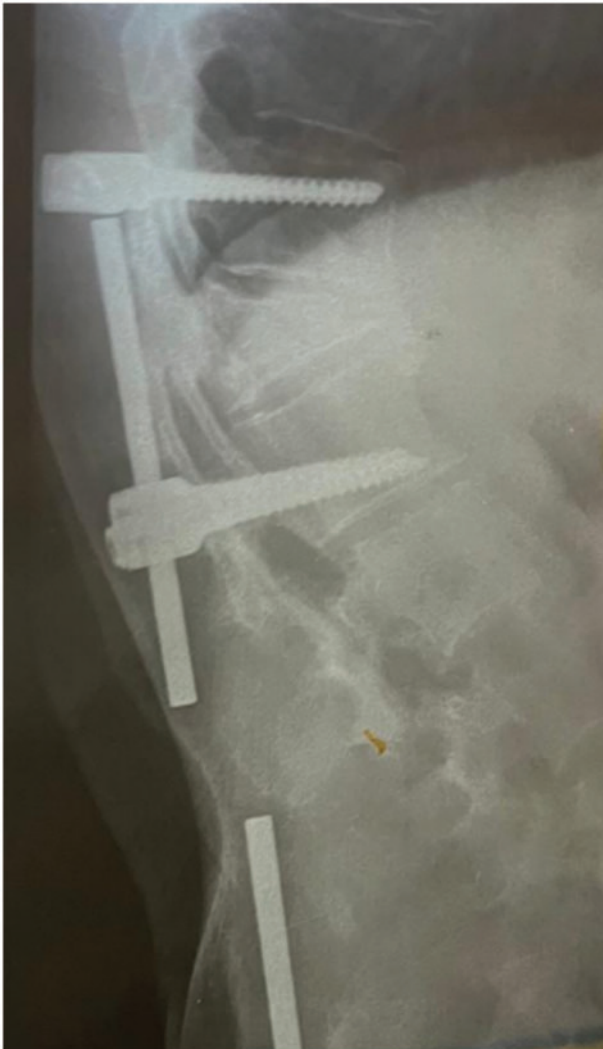

Fig. 2. Standard radiology of the dorsolumbar spine in profile, showing secondary displacement of the osteosynthesis hardware.

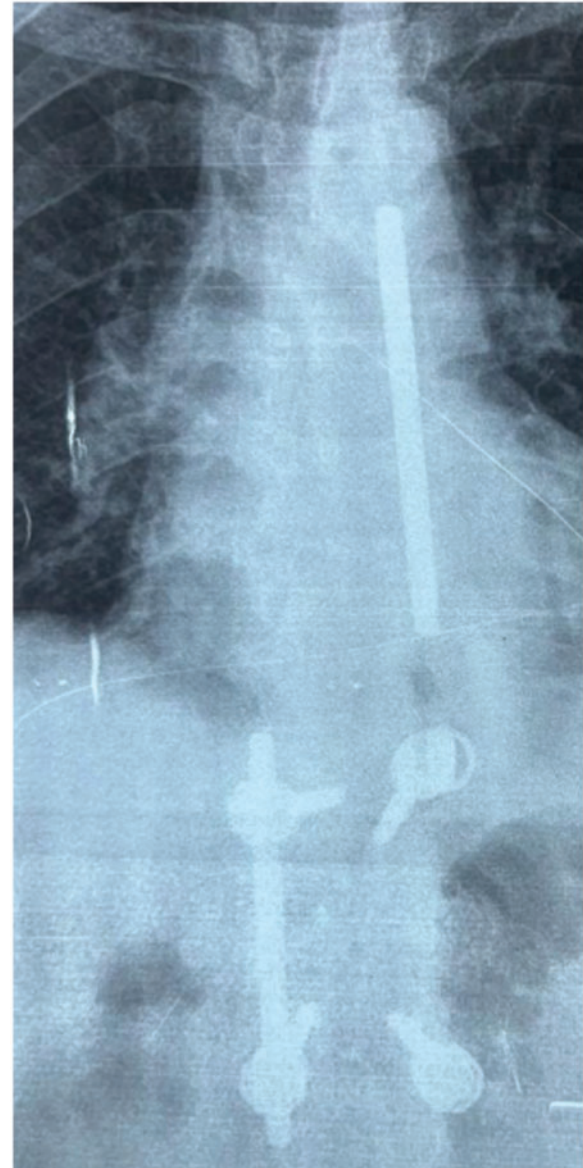


Fig. 3. Standard radiology of the dorsolumbar spine from the front, showing secondary displacement of the osteosynthesis hardware.

4. THERAPEUTIC MANAGEMENT

4.1. Infectious Complications

All our patients who presented with an infectious complication benefited from analgesic treatment combined with probabilistic antibiotics combining a C3G (ceftriaxone 50 mg/kg/dr) and an aminoglycoside (gentamycin 3–4 mg/kg/dr); except in one case of documented *Escherichia coli* infection, which required amikacin 1 g/dr for 10 days. In addition, the two cases of *Pseudomonas aeruginosa* infection received the same dose of Amikacin plus Colimicyne at a dose of 50000 µg/kg/dr in 2 slow infusions over at least one hour. Eight patients with an infectious complication received medical treatment alone, i.e., 38.1% of cases, while 14 patients had osteosynthesis material removed in association with medical treatment (66.66% of cases). All patients were systematically treated postoperatively with level 1 or 2 analgesics. Curative-dose anticoagulant therapy was beneficial and was instituted in patients with post-operative deficits.

4.2. Mechanical Complications

In our study series, all patients presenting with a mechanical complication underwent a surgical revision for

the removal of osteosynthesis material. All patients were given level 1 or 2 analgesics postoperatively. Curative-dose anticoagulant therapy was beneficial and was instituted in patients with post-operative deficits.

Among 43 patients who had one or more complications of varying severity, one case of death was reported, representing a mortality rate of 2.32% of the total number of patients admitted for the complication of post-traumatic dorsolumbar spine surgery.

In this case, a patient undergoing chemotherapy for Rhabdomyosarcoma of the Psoas was admitted for externalization of osteosynthesis material opposite the lumbar spine, with a febrile sensation, altered general condition and 0/5 paraplegia. She underwent surgery on 02 consecutive days, with removal of the osteosynthesis hardware (4 screws and 2 plates) and medical treatment. The post-operative was marked by a deterioration in her condition.

In our series, 42/43 patients, i.e., 97.67%, had a favourable outcome after specific treatment of the various post-operative complications on a case-by-case basis,

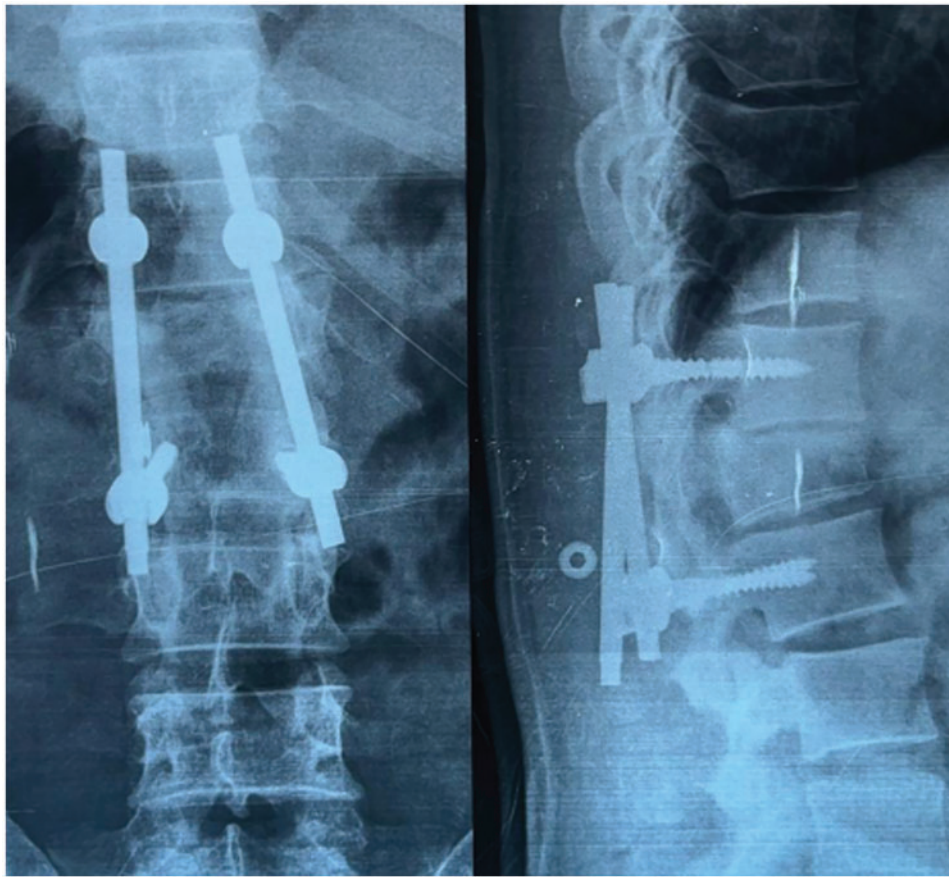


Fig. 4. Standard radiology of the dorsolumbar spine, front (*left*) and profile (*right*), showing unravelling of the osteosynthesis material in the dorsolumbar spine.

with regression of neurological signs (motor and sensory), Genito-sphincter disorders and improvement in general condition in all cases.

5. DISCUSSION

Lumbar spine surgery is a complex surgical procedure that aims to treat problems related to the lumbar spine. Although lumbar spine surgery can be an effective treatment option for many conditions, it can also lead to certain complications (Fig. 5). In this article, we will look at the possible complications of lumbar spine surgery. Post-operative infection surgical site infection is one of the most common infectious complications of lumbar spine surgery. It occurs when bacteria or germs enter the surgical wound and cause an infection. Symptoms may include fever, chills, pain, redness and swelling around the surgical site. Patients should be closely monitored after the operation for any possible infection. Urinary tract infection is another infectious complication that can occur after lumbar spine surgery. Patients may be catheterized during the operation, which may increase the risk of UTIs. Symptoms may include pain or burning with urination, frequent urination, and fever. Post-operative pneumonia 5,71% is a serious infectious complication that can develop after lumbar spine surgery (Fig. 6). It occurs when bacteria or germs enter the lungs and cause an infection. Patients may be at increased risk of developing post-operative pneumonia if they smoke, have a history of lung disease, or if the

operation requires prolonged intubation. Intervertebral disinfection is a rare but serious infectious complication that can develop after lumbar spine surgery. It occurs when bacteria or germs enter the intervertebral disc and cause an infection. Symptoms may include pain, fever, chills, and spinal stiffness. Post-operative meningitis is a rare but serious infectious complication that can occur after lumbar spine surgery. It occurs when bacteria or germs enter the membranes that surround the brain and spinal cord. Symptoms may include fever, headache, nausea and vomiting, stiff neck, and changes in consciousness.

Post-operative pain is a common complication of lumbar spine surgery. The pain can be mild to severe and can last for several weeks after the operation. Patients may require analgesics to relieve their pain. Patients undergoing lumbar spine surgery may develop a post-operative hematoma under the skin, which can cause swelling and pain. In some cases, a hematoma may require surgery to be removed.

5.1. Anaesthesia-Related Complications

General anaesthesia can lead to complications, including an allergic reaction, decreased blood pressure, slowed or stopped breathing, and post-operative confusion. Patients should be closely monitored after the operation for any anaesthesia-related complications.

Lumbar spine surgery can lead to nerve damage. Spinal nerves can be compressed or damaged during surgery, causing pain, numbness, or muscle weakness. Nerve damage can be temporary or permanent.

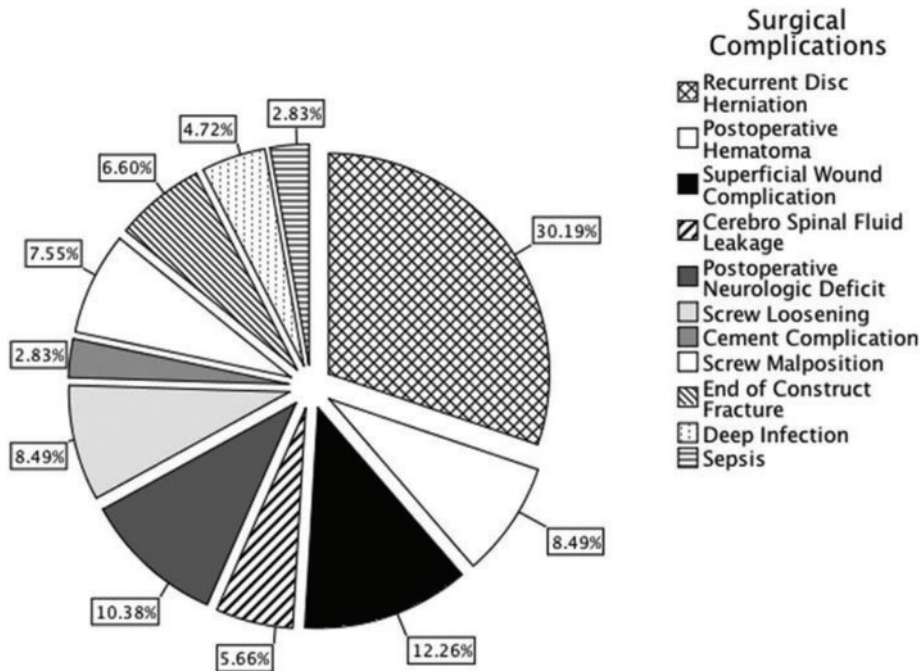


Fig. 5. Distribution of surgical complications according to the literature (Source: [5]).

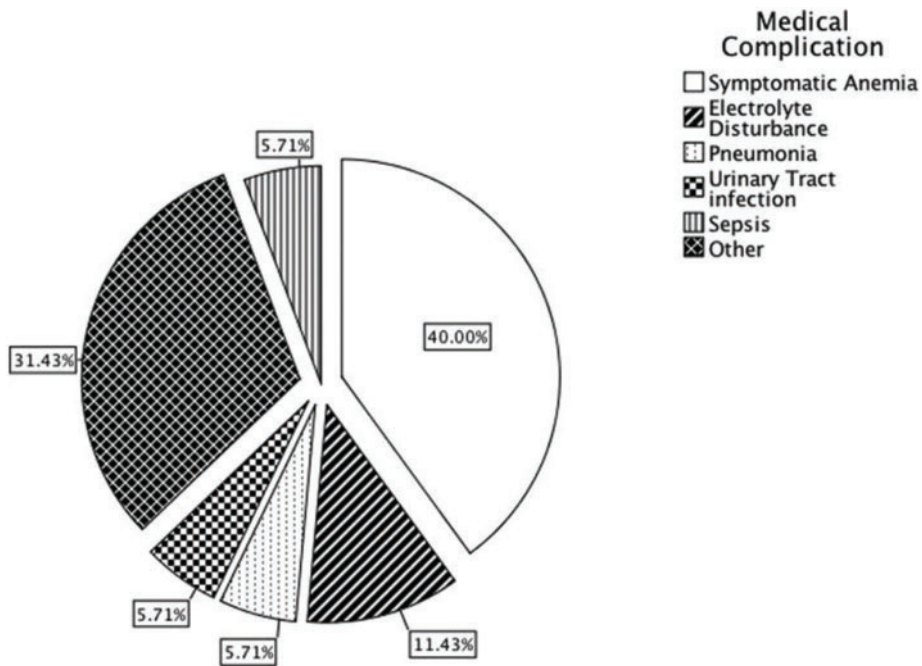


Fig. 6. Distribution of medical complications according to the literature (Source: [5]).

5.2. Spinal Instability

Lumbar spine surgery can lead to spinal instability. This can happen if the spine is weakened, or parts of the spine are removed during the operation. Spinal instability can lead to pain or disability to move. Deep vein thrombosis is a serious complication of lumbar spine surgery. It happens when blood clots form in the deep veins of the legs.

5.3. Various Factors and Risk Factors Associated with Complications and Morbidities in Patients Undergoing Spine Surgery

The authors refer to previous studies that have examined these factors. The American Society of Anesthesiologists

(ASA) grade is identified as a significant risk factor for major complications. Studies have found that higher ASA grades are associated with increased complication rates and higher costs. The complexity of surgical procedures is also found to be associated with longer stays in the intermediate care unit (IMC) and overall hospitalization. Higher complexity classes are linked to increased risks of prolonged IMC stay and extended hospital stay. Advanced age is identified as a risk factor for complications and morbidity after surgery. Patients over 80 years old have a higher mortality risk and increased chances of infection. However, older patients who undergo lumbar decompression surgery for degenerative lumbar spinal stenosis can

still experience significant improvements in various outcome measures. Body mass index (BMI) is mentioned as a potential risk factor for complications in spine surgery. Obesity is associated with a higher risk of infection and other complications. However, the present study does not demonstrate a significant association between BMI and the outcomes analyzed. The study has certain limitations, including its retrospective nature, potential bias, and the need for further refinement and validation of the proposed surgical complexity classification. Surgeon experience and hospital volume of spine surgical cases are mentioned as factors that may impact complication rates. Based on their findings, the authors suggest optimizing preoperative factors such as laboratory values and discontinuing corticosteroids when possible. Surgeons should also consider the complexity of the procedure and inform patients about the potential for an irregular perioperative course.

The actual frequency of complications of operated dorsolumbar spine trauma is difficult to estimate in our context, as well as in the literature, due to the few studies carried out in this area.

In our series, the frequency of post-operative complications was 19.72%, which is similar to other national studies. In a study carried out in the Neurosurgery Department of the Mohammed VI University Hospital in Marrakech over a 5-year period from 2003 to 2007 by DERHEM [1], complications of operated dorsolumbar spine trauma accounted for 14% of complications. In the series by SEDDIK [2], these complications accounted for 15.04% of all dorsolumbar operated in the Neurosurgery Department of the AL GHASSANI Hospital at the Hassan II Hospital in Fez over a 7-year period from 2001 to 2007.

The mean age of our patients was 41.43 years, with extremes ranging from 16 to 80 years. The most affected age group was 16–30 years, corresponding to 32.56% of patients in our series, which correlates with other published studies [1]–[4].

6. CONCLUSION

This study highlights the complication rates of surgery for traumatic thoracolumbar spine pathology in the neurosurgical emergency department. The identification of risk factors and the understanding of these complications will improve preoperative planning and advice to patients in order to optimize the management of these cases. Careful monitoring and proper management of post-operative complications are necessary to ensure better patient outcomes.

CONFLICT OF INTEREST

The authors declare that they do not have any conflict of interest.

REFERENCES

- [1] Derhem N. Management of thoracolumbar spine trauma at the Mohammed VI University Hospital in Marrakech [La prise en charge des traumatismes du rachis dorsolombaire au CHU

- Mohammed VI de Marrakech]. Dissertation, Marrakech: Cadi Ayyad University; 2008.
- [2] Seddik Y. Trauma to the thoracolumbar spine (About 246 cases) [Les traumatismes du rachis dorso-lombaire (A propos de 246 cas)]. Dissertation, Fès: Cadi Ayyad University; 2009.
- [3] Verlaan JJ, Diekerhof CH, Buskens E, Van der Tweel I, Verbout AJ, Dhert WJ, *et al.* Surgical treatment of traumatic fractures of the thoracic and lumbar spine: a systematic review of the literature on techniques, complications, and outcome. *Spine*. 2004 Apr 1;29(7):803–14.
- [4] Kreinest M, Rillig J, Grützner PA, Küffer M, Tinelli M, Matschke S. Analysis of complications and perioperative data after open or percutaneous dorsal instrumentation following traumatic spinal fracture of the thoracic and lumbar spine. *Eur Spine J*. 2017;26(5):1535–40.
- [5] Farshad M, Aichmair A, Gerber C, Bauer DE. Classification of perioperative complications in spine surgery. *Spine J*. 2020 May 1;20(5):730–6.