

# Congenital Insensitivity TO Pain: A Case Report

Hind Hamdani, Naoual Mtalai, Sara Ennaki, Ghizlane Daghouj,  
Loubna El Maaloum, Bouchra Allali, and Asmaa El Kettani

## ABSTRACT

**Congenital insensitivity to pain or more scientifically Hereditary sensory and autonomic neuropathies (HSAN) is a rare genetic disorder which associates a sensory dysfunction with a varying degree of autonomic dysfunction. Due to the peripheral neuropathy, a decreased sensitivity or even complete anesthesia may be present resulting in, on the ophthalmological level, neurotrophic ulcers. We report the case of 2 sisters (JM and KM) presenting with HSAN with recurrent corneal ulcers. Unfortunately, genetic testing couldn't be performed due to lack of means, but the clinical presentation and features were very favourable or even pathognomonic of this syndrome. The first cases or reported individuals presenting with congenital insensitivity to pain goes back to 1930's. Five types of hereditary sensory and autonomic neuropathy have been identified according to age of onset of symptoms, clinical features and affected gene. HSAN type IV also known as congenital insensitivity to pain with anhidrosis (CIPA) is the second most common HSAN. It is caused by mutation in the NTRK1 (Neurotrophic tyrosine kinase receptor type 1) (TRKA) gene located in chromosome 1 (1q21-q22). It is characterized by repetitive hyperthermic episodes in infancy, and mental retardation is usually present, as reported in our case. Clinical symptoms of pain insensitivity manifest as tongue, lip and fingers biting, and self-inflicted injuries. Congenital insensitivity to pain is a rare genetic syndrome characterized by an absence or an altered response to pain. Individuals with this syndrome can presented self-inflicted injuries and auto-mutilation leading in some cases to severe disabilities. Long-term visual prognosis in CIPA patients is not assessed and there's an important lack of data regarding ocular manifestation of CIP syndrome.**

**Keywords:** Autonomic neuropathy, congenital insensitivity to pain, corneal ulcerations, genetic disorder.

**Submitted :** April 24, 2023

**Published :** July 26, 2023

**ISSN:** 2593-8339

**DOI:** 10.24018/ejmed.2023.5.4.1782

### H. Hamdani\*

Department of Pediatric Ophthalmology,  
CHU Ibn Rochd-Hassan II University,  
Casablanca.

(e-mail: hiind.hamdani@gmail.com)

### N. Mtalai

Department of Pediatric Ophthalmology,  
CHU Ibn Rochd-Hassan II University,  
Casablanca.

### S. Ennaki

Department of Pediatric Ophthalmology,  
CHU Ibn Rochd-Hassan II University,  
Casablanca.

### G. Daghouj

Department of Pediatric Ophthalmology,  
CHU Ibn Rochd-Hassan II University,  
Casablanca.

### L. El Maaloum

Department of Pediatric Ophthalmology,  
CHU Ibn Rochd-Hassan II University,  
Casablanca.

### B. Allali

Department of Pediatric Ophthalmology,  
CHU Ibn Rochd-Hassan II University,  
Casablanca.

### A. EL Kettani

Department of Pediatric Ophthalmology,  
CHU Ibn Rochd-Hassan II University,  
Casablanca.

\*Corresponding Author

## I. INTRODUCTION

Congenital insensitivity to pain or more scientifically Hereditary sensory and autonomic neuropathies (HSAN) is a rare genetic disorder which associates a sensory dysfunction with a varying degree of autonomic dysfunction. Five types of hereditary sensory and autonomic neuropathy have been identified according to age of onset of symptoms, clinical features and affected gene. Due to the peripheral neuropathy, a decreased sensitivity or even complete anesthesia may be present resulting in, on the ophthalmological level, a neurotrophic ulcers.

We report the case of 2 sisters presenting with HSAN IV with recurrent corneal ulcers.

## II. CASE REPORT

KM and JM are 2 sisters who are respectively 4 years and 2 1/2 years old, from a non-consanguineous marriage.

KM was a healthy baby girl, born at term, with a weight of 2,8 Kg with no noticeable incident during the pregnancy. Her development was age appropriate, however, she had recurrent respiratory infections, recurrent corneal ulcers, and was hospitalized 3 times for febrile seizure and febrile episodes. At the evaluation, the infant was 6 month and couldn't stand with support. The ophthalmological examination showed a negative blink reflex, corneal ulceration on both eyes (Fig. 1). Tear break-up time could not be evaluated due to the age of the patient. The general examination showed sparse hair, scalloped lips, and healing ulcers of the lips, thumb and index (Fig. 1, 2) In view of the clinical findings recurrent corneal and fingers ulcerations, and the suspicion of anhidrotic

ectodermal hypoplasia, the diagnosis of congenital insensitivity to pain was evoked.

Additional complementary examination was ordered including an ENMG and a genetic study of both parents and child. Due to a lack of resources, only the ENMG could be carried out, showing an absence of sensory responses in the lower limbs. Genetic counselling was carried out, and antibiotics drops, hourly artificial tears and a night lubricating gel were prescribed.

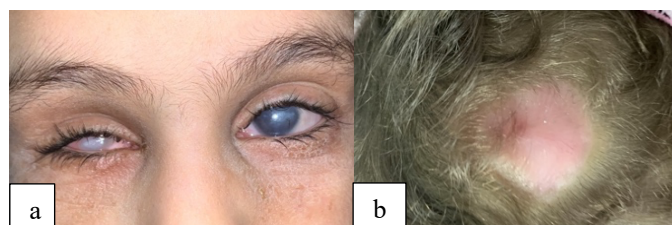


Fig. 1. a) dry eye with dry and skin, b) Sparse hairthin.

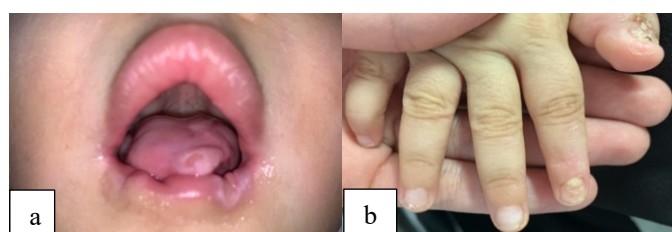


Fig. 2. a) Tongue ulcers and biting marks, b) Biting nails (thumb and index).

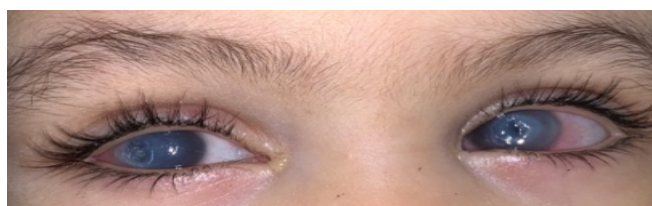

Fig. 3. Corneal ulceration on both eyes.

Unfortunately, parents have been lost from sight. After 2 years they came back for the same symptoms with their 2nd daughter, JM.

Given the history and the development of similar symptoms as her older sister, the diagnosis of insensitivity to pain was made for JM without further examination given the socio-economic situation of the parents.

An examination of the older sister, 2 years after, showed a mental retardation with corneal opacities in both eyes, finger

and lips ulcerations (Fig. 3, 4) Given the context, dental extraction has been started for both girls in order to reduce self-mutilation, and we maintained lubricant eye drop. Written informed consent was obtained from the patient for publication of this case report and accompanying images.

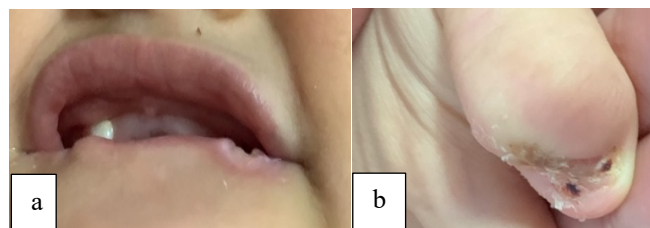


Fig. 4. a) Child biting her lower lip, b) Biting nail.

### III. DISCUSSION

The first cases or reported individuals presenting with congenital insensitivity to pain goes back to 1930's (Dearborn 1932) [1]. It was at this point that doctors and scientist became interested. Over the years two groups have been distinguished. First is congenital insensitivity to pain where the individual does not perceive the sensation of pain his type or intensity. Second is congenital indifference to pain, unlike the other, the individual does perceive the pain but do not react to it, hence there is no lack of signal transmission in this second group [1].

The majority of infant and children with congenital insensitivity to pain have hereditary sensory and autonomic neuropathy (HSAN). At this time, 5 type of HSAN have been identified according to age of onset of symptoms, clinical features and affected gene (Table I).

HSAN type IV also known as congenital insensitivity to pain with anhidrosis (CIPA) is the second most common HSAN [1]. It is a rare autosomal recessive syndrome, more common in Jewish and Japanese population. Haga *et al.* estimated type IV HSAN to 1 / 600000 – 950000 in Japanese population, but there's a lack of epidemiological studies about CIPA around the world [3].

It is caused by mutation in the NTRK1 (Neurotrophic tyrosine kinase receptor type 1) (TRKA) gene located in chromosome 1 (1q21-q22). It encodes a receptor tyrosine kinase (RTK) which is autophosphorylated in response to NGF (Nerve Growth Factor). Therefore, due to the mutation, there's an alteration of the signal impeding cell growth in the sensory fibers. [2],[4].

TABLE I: DIFFERENT TYPES OF HSAN[2]

	HSAN 1	HSAN 2	HSAN 3	HSAN 4	HSAN 5
Inheritance	Autosomal dominant	Autosomal recessive	Autosomal recessive	Autosomal recessive	Autosomal recessive
Age of onset	Second decade	Infancy	Birth	Birth	Birth
Insensitivity to pain	++	++	+	++	+
Sweating	Normal	Normal	Decreased	Normal	Normal
Ophthalmic manifestation	Not reported	Slow blink reflex	Alacrima and Corneal anaesthesia	Corneal anaesthesia	Corneal anaesthesia
Mental retardation	-	+/-	+	++	+/-
Muscle hypotonia	Absent	Absent	+	Absent	Absent
Biopsy	Loss of UF>MF	Absent MF	Reduced UF	Absent UF	Absent/small MF
Genes	SPTLC1 SPTLC2 ALT1 DNMT1	WNK1 RETREG1	IKBKAP	NTRK1 PRDM12	NGF B NTRK1

Notes. UF – Unmyelinated fibres, MF- Myelinated fibres , AR – Autosomal recessive, AD – Autosomal Dominant

It is characterized by repetitive hyperthermic episodes in infancy, and mental retardation is usually present, as reported in our case. Clinical symptoms of pain insensitivity manifest as tongue, lip and fingers biting, and self-inflicted injuries [1], [2], [4]. On the ophthalmological level, ocular manifestations of congenital insensitivity to pain with anhidrosis range from dry eye syndrome, superficial punctate keratitis (SPK), corneal opacities, neurotrophic keratopathy and corneal ulcers [2], [5].

Recurrent corneal ulcers are due either to decreased or absence of corneal sensitivity, in this case we call them neurotrophic ulcers, or are due to self-inflicted traumatism within the context of self-mutilation. Recurrent corneal ulcers end up in a corneal opacity leading to vision loss. Surgical treatment such as corneal graft have not been associated with a high risk of failure [6].

Long-term visual prognosis in CIPA patients is not assessed and there's an important lack of data regarding ocular manifestation of CIP syndrome [5].

#### IV. CONCLUSION

Congenital insensitivity to pain is a rare genetic syndrome characterized by an absence or an altered response to pain. Individuals with this syndrome can presented self-inflicted injuries and auto-mutilation leading in some cases to severe disabilities. The majority of management consists of symptomatic treatment of all manifestations.

The limited data on CIP syndrome encourages us to take a greater interest in it in order to improve the management of these patients.

#### CONFLICT OF INTEREST

Authors declare that they do not have any conflict of interest.

#### REFERENCES

- [1] Nagasako EM, Oaklander AL, Dworkin RH. Congenital insensitivity to pain: an update. *Pain*. 2003; 101(3): 213-9.
- [2] Suresh B, Reddy V, Kurth I, Jagadeesh S. A Child Presenting with Recurrent Corneal Ulcers: Hereditary Sensory and Autonomic Neuropathy IV (HSAN IV). *Neuro-Ophthalmol*. 2019; 43(5): 310-2.
- [3] Haga N, Kubota M, Miwa Z. Epidemiology of hereditary sensory and autonomic neuropathy type IV and V in Japan. *Am J Med Genet A*. 2013; 161(4): 871-4.
- [4] Axelrod FB, Gold-von Simson G. Hereditary sensory and autonomic neuropathies: types II, III, and IV. *Orphanet J Rare Dis*. 2007; 2(1): 39.
- [5] Elsana B, Gradstein L, Imtirat A, Yagev R, Barrett C, Ling G, et al. Ocular manifestations of congenital insensitivity to pain: a long-term follow-up. *Br J Ophthalmol*. 2021.
- [6] Schon KR, ChB M, Parker APJ, Woods CG, ChB M. *Congenital Insensitivity to Pain Overview*. 2020.